

BRIEF ERGONOMIC REVIEW CARDIAC ULTRASOUND

Prepared for:

M. Lovick

Health Sciences Association

#300-5118 Joyce Street

Vancouver, BC, V5R 4H1

Prepared by:

Carmel Murphy, MSc. CCPE

Report Date: June 2012

Confidential Disclosure, all rights reserved.

BACKGROUND

In May 2012, FORME Ergonomics was contracted by Marty Lovick, Senior Labour Relations Officer, Health Sciences Association of British Columbia, to investigate a query from a number of members regarding insufficient information on cardiac ultrasonography contained in the Best Practices for Diagnostic Medical Sonographers package recently released by the Health Sciences Association. The objective was to complete a brief review of ergonomic concerns present in cardiac ultrasonography and determine whether additional information on this type of diagnostic sonography could be provided.


On May 29th, Carmel Murphy, RPT, CCPE met with two cardiac sonographers at Peace Arch Hospital, Fraser Health Authority and observed them performing a variety of cardiac ultrasounds

The following report and associated recommendations is based on observations and interviews made during the site visit with the above staff and provides the following information obtained during this assessment.

- Methods used for cardiac ultrasounds
- Similarities with other scanning types
- Differences with other scanning types
- Work practice recommendations

Please do not hesitate to contact FORME Ergonomics if you have any questions.

Sincerely



Carmel Murphy, MSc. CCPE, CDMP

METHODS USED FOR CARDIAC ULTRASOUNDS

- Cardiac ultrasounds are performed for a variety of cardiac conditions and are performed using an ultrasound transducer and a small single crystal transducer (See Figures 1 and 2).
- A range of viewing windows are used with the patient positioned in left side lying, supine lying or right side lying. The majority of images are captured with the patient in left side lying (See Figure 3, 4, 5).
- A minimum of four viewing windows are used e.g. para-sternal long and short view, apical, suprasternal, or subcostal views.
- Cardiac ultrasound requires dynamic images to be captured, necessitating precise positioning of the transducer between the ribs at specific viewing angles while attempting to have minimum disturbance of the image from air movement. Generally this requires the patient to hold their breath at specified times so that images can be captured. Approximately 60-70 images are captured per scan.
- Depending on the complexity of the scan, scanning time can range from 30 minutes to over 1 hour.
- Scans are completed with the left hand and image capture is completed with the right hand by manipulating machine dials and controls. Repetition rates for the right hand were reported in the range of 500-600 clicks per completed scan (not verified during the assessment).
- At the facility above, 14 scans are completed by two technologists per day, they share the same machine and alternate scans with analysis at 40 minute intervals.
- Following image capture, the technologist then completes an analysis of the scan at a designated computer workstation. This consists of reviewing images captured, completing measurements within of images and writing up a sonographer report. This is a mouse intensive task.

SIMILARITIES WITH OTHER SCANNING TYPES

- Involves use of both hands. Ultrasound scans are commonly performed with the right hand and images are captured with the right hand whereas with cardiac ultrasounds, scanning is performed with the left hand and images are captured with the right hand.
- Involves use of a transducer using a transmission gel in contact with the patient.
- Requires careful positioning of the patient to reduce awkward postures of shoulder, arm, wrist and fingers for the technician. Similar awkward positions of shoulders, neck, elbow, wrist and hand noted with other types of scanning.
- Multiple scans are performed during a shift.

DIFFERENCES WITH OTHER SCANNING TYPES

- A dynamic image needs to be captured. Ultrasound is not transmitted through bone or air. For cardiac ultrasounds, the transducer has to be placed between the ribs and there has to be minimal air or movement interference. This generally requires the ultrasound transducer to be located in a very small area. Once the correct spot is located a sustained pressure is exerted through the transducer and multiple images are captured. If the patient moves or breathes deeply the transducer needs to be repositioned. Given the limited space between the ribs the full head of the transducer is not used under most circumstances. A small corner of the transducer is generally used to capture the images.
- Apical views of the chest wall require the transducer to be positioned under the breast. Body habitus has an impact on ease of placement and maintenance of position of the transducer. Certain body types require more pressure through the transducer to access the area between the ribs or body tissues have to be supported while using the transducer. This has an impact on the amount of force and static activity required in the left upper extremity, neck and trunk.
- Two types of transducers are used. The single crystal transducer has a T-shape and requires a different hand grip compared to a regular transducer. To obtain a clear image, the transducer has to be placed precisely and pressure needs to be maintained while the image is captured.
- High forces are required to hold the transducer in place. Patients noted they felt a strong pressure, estimated as greater than 2kg of force through the hand and fingers. For some scans, the technologists positioned the patient bed at a lower height and used their arm and body to maintain the transducer position. The clarity of the images captured was observed to be directly related to how successfully the transducer was placed and held in the viewing position.
- When in position, the transducer was observed to move only minimally and the position was held for several minutes. The technologist uses very fine motor movements that are barely visible. They noted these sustained positions result in fatigue and discomfort. At times they use their right hand to manipulate the transducer while maintaining the location and pressure on the transducer with the left hand.
- Both a palm up and palm down position is used when scanning. This position is dependent on which view is being taken or which transducer is being used. Some positions are recommended for particular viewing locations. It can be challenging to maintain a neutral wrist and hand position, given the small windows for viewing, number of images required and patient body habitus.
- Towels can be used to support the wrist and forearm in position. Precise positioning using cushions may be challenging given the range of body sizes and types. There was not an opportunity to explore this further during this assessment.

- Technologists reported that it is extremely difficult to switch from left handed to right handed scanning, due to the amount of precision and tactile expertise required for this type of scanning.




Figure 1: Regular Transducer

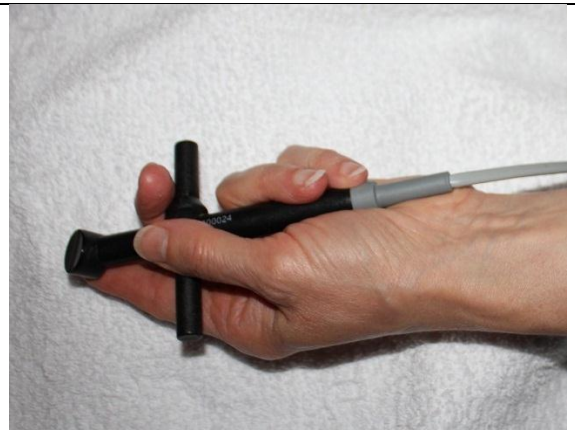

Figure 2; Single Crystal Ultrasound Transducer, note grip required.

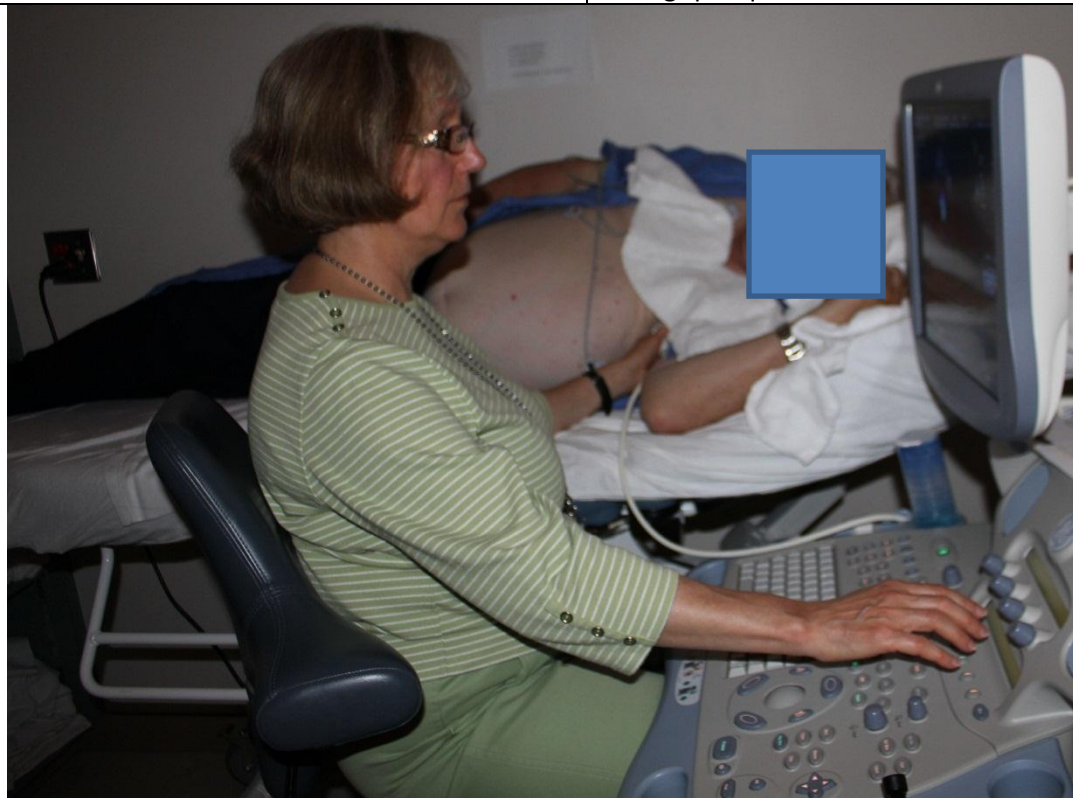

Figure 3: Scanning Position Sitting

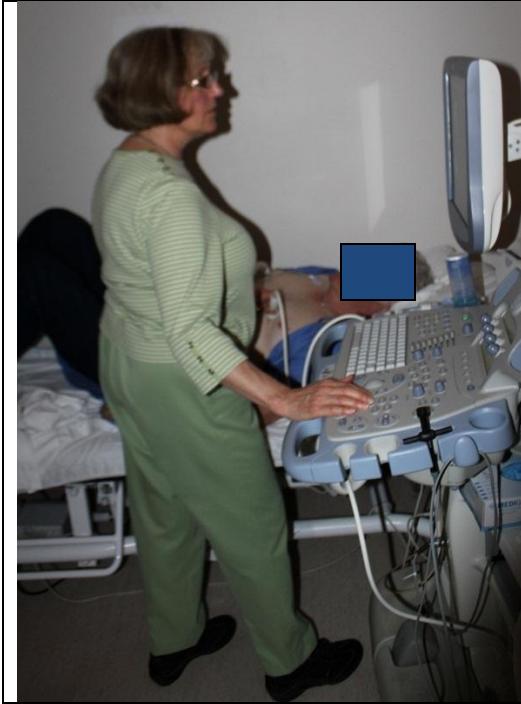


Figure 4: Scanning Position Standing

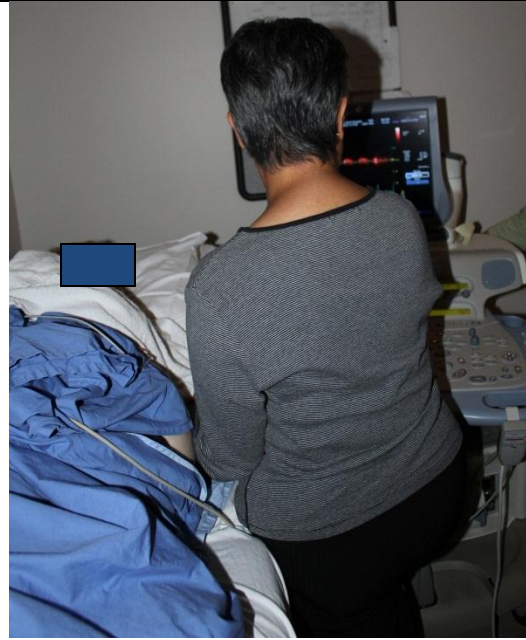


Figure 5: Scanning Position Standing Using Arm and Hip for support

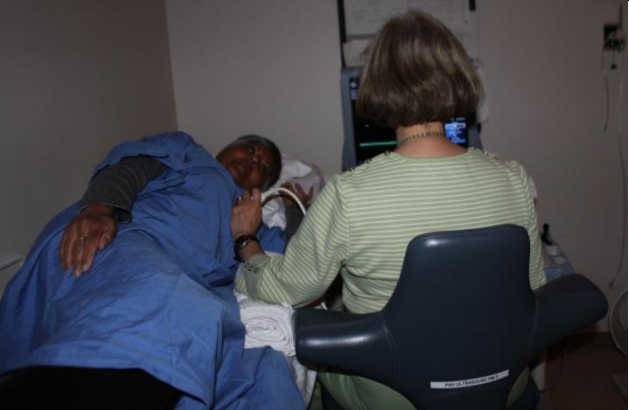RECOMMENDATIONS

Know Your Risks

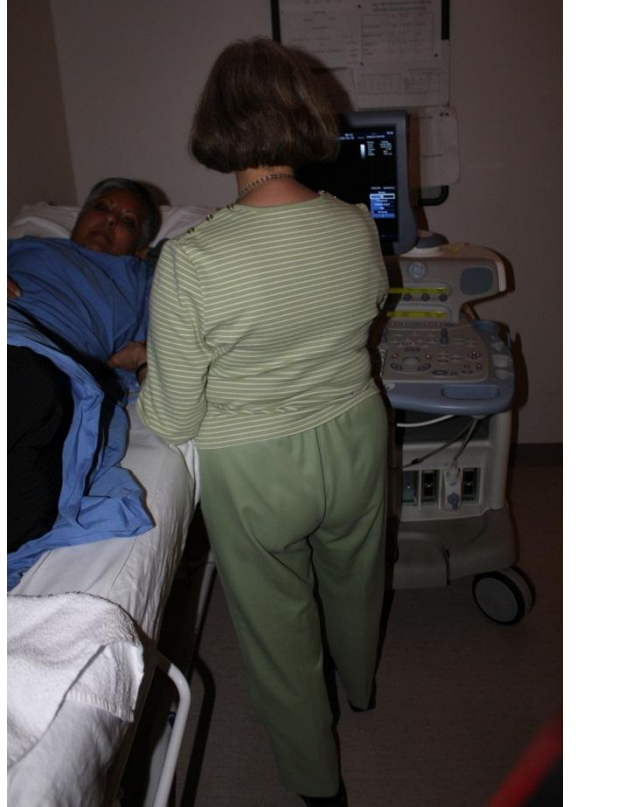
Cardiac scans can cause awkward and sustained shoulder, wrist, hand and spinal postures. Different types of transducers are used and these are positioned in small areas, such as between the ribs or close to the sternum. Once in position, the transducers are held in position in a predominantly static position while multiple, dynamic images are captured. Sustained and awkward postures are fatiguing and can increase the risk of pain and injury.

Consider Your Options

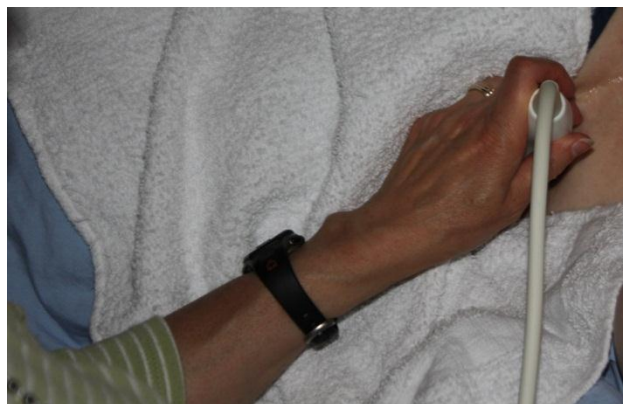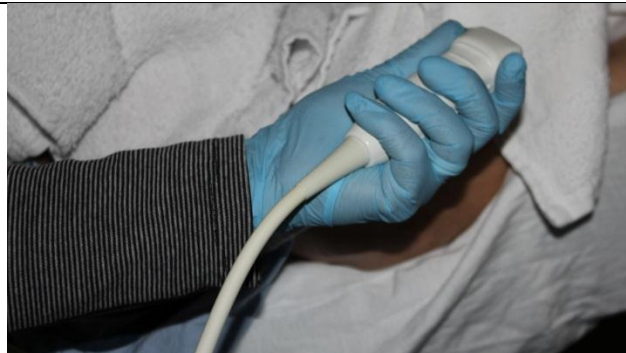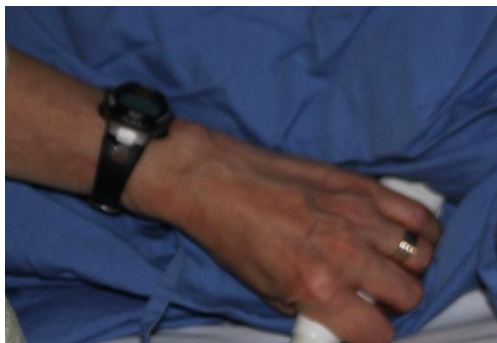1. Follow best practices for adjusting your workstation and equipment as outlined in the general guideline (ADJUSTING YOUR WORKSTATION AND EQUIPMENT). Keep arms as close to the body as possible.



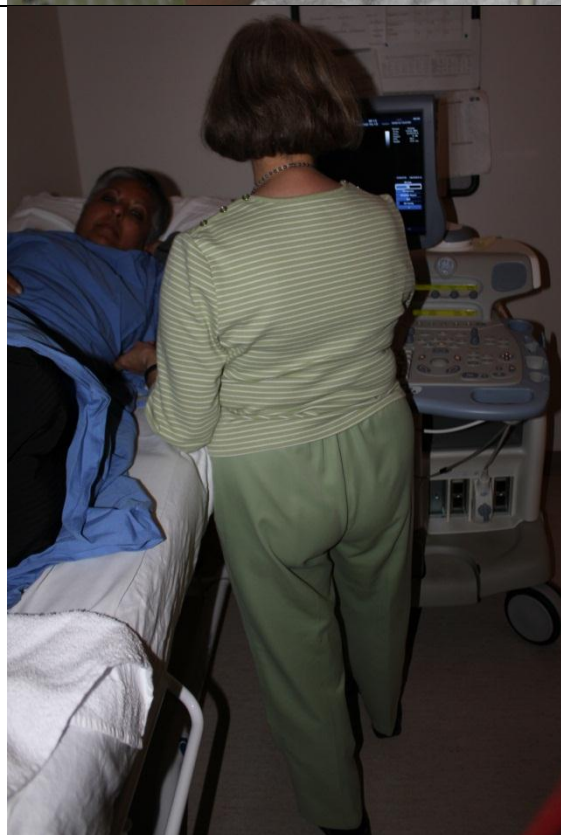2. Adjust the height of the patient on the bed so that you can work with a neutral shoulder posture while scanning. If possible adjust the height so you can move from an optimal sitting posture to standing posture mid-way through a scan without requiring additional height adjustment of the bed. A standing work posture alternates muscle activity, allows use of larger muscle groups and provides additional leverage and force while holding the transducer.



3. Ensure you use a neutral wrist posture. Depending on the scanning window this will require changing your grip from a palm up to a palm down position.

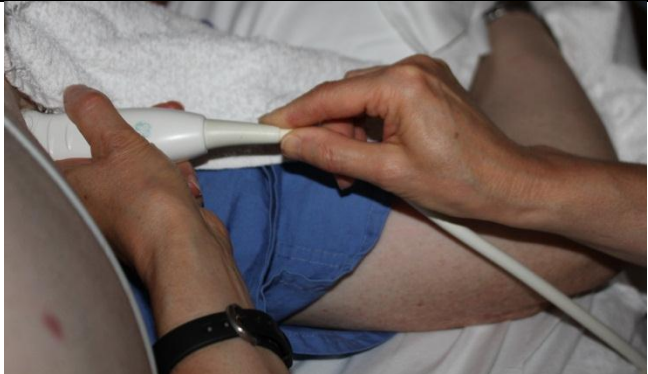

4. To obtain a clear image where larger hand and arm forces are needed, it can be helpful to support your elbow against your side and use your body weight to hold the transducer in place, thus reducing the forces required.

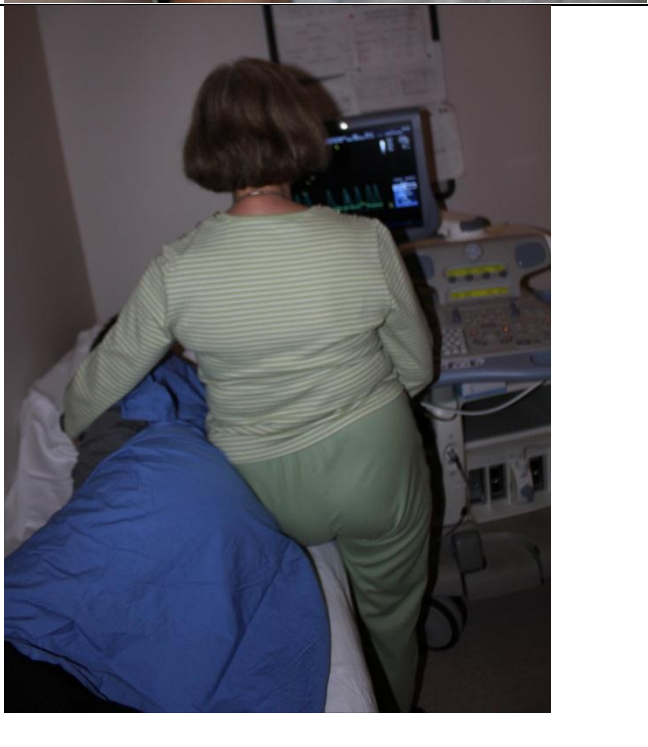

5. Use your right hand for fine tune positioning of the transducer and to relieve pressure on the left hand and arm.

When using the single crystal transducer, use different muscles by alternating the grip from the index to middle and ring fingers.



6. Get as close to the patient as possible. If available, use apical cuts out on the bed.



OTHER

- When performing scans of the right parasternal area reduce neck and spine rotation by repositioning the monitor and control panel in front of you.
- Relax your hand periodically by releasing pressure on the probe handle after capturing an image.
- If possible, take micro breaks during the scan and perform dynamic muscle movements.